

CASE REPORT

Open Access



# Primary intraosseous osteolytic meningioma: a case report and review of the literature

Sae Min Kwon<sup>1,2</sup>, Yong Ko<sup>1\*</sup>  and Seong Sik Bang<sup>3</sup>

## Abstract

**Background:** Primary intraosseous meningioma is a subset of extradural meningioma that arises in the bone, and only a few cases have been reported to date.

**Case presentation:** An 80-year-old man presented with decreased hearing on the right side accompanied by a disturbance of balance 10 months prior to admission. Magnetic resonance imaging revealed an 8 × 7 cm osteolytic mass in the right posterior fossa related to the petrous bone, with extension to the cervical region. During surgery, the tumor was found to be located extradurally, with no invasion of the dura. The tumor was removed entirely, apart from a small portion around the jugular foramen to avoid lower cranial nerve injury.

**Conclusion:** The final diagnosis was primary intraosseous osteolytic meningioma with atypical pathology. Here, we report a rare case of an osteolytic skull lesion in the skull base not invading the dura and with extensive bone destruction.

**Keywords:** Intraosseous, Meningioma, Osteolysis

## Background

Meningiomas are common intradural lesions that arise from the arachnoid cap cells of the arachnoid layer. In contrast, primary extradural meningioma is a relatively rare entity, accounting for less than 2% of all meningiomas [1, 2]. They may arise from other locations, such as the skin, orbit, nasopharynx, and neck [3–5]. Primary intraosseous meningioma, which arises in the bone, is a subset of primary extradural meningioma, and only a few cases have been reported [1, 3]. Here, we report a recent case of primary intraosseous osteolytic meningioma with extension to the cervical region which was successfully removed.

## Case presentation

An 80-year-old man presented with a progressive decrease in hearing on the right side accompanied by dizziness and disturbance of balance 10 months prior to admission. The neurological examination revealed right

hypoglossal nerve palsy. Audiometry documented complete sensorineural hearing loss on the right side.

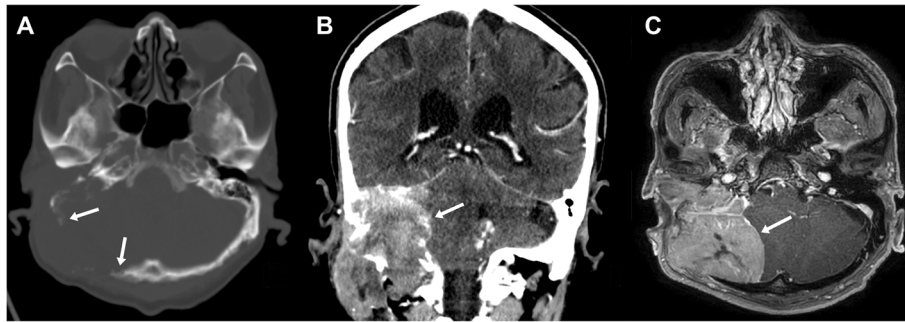
Skull x-ray and cranial computed tomography (CT) scans showed a large osteolytic lesion with bone destruction, including the temporal bone, occipital bone, clivus, jugular foramen, and hypoglossal canal (Fig. 1a and b). Magnetic resonance imaging (MRI) revealed an 8 × 7 cm homogeneous enhancing mass in the right posterior fossa related to the petrous part of the temporal bone, with extension to the cervical region (Fig. 1c). The cerebellum was displaced, and definite brain invasion was not seen. The preoperative diagnosis was a temporal bone origin malignancy such as squamous cell carcinoma or meningioma with invasion of the petrous bone.

The patient underwent surgery to obtain a pathological diagnosis and for complete removal of the mass. A C-shaped postauricular skin incision was made that extended to the neck. The scalp was reflected anteriorly, and the mass infiltrating the subcutaneous tissue was exposed. The lesion appeared as a firm gray mass that had destroyed the temporal and occipital bones. The dura was intact with no invasion, and the lesion

\* Correspondence: [koy8497@hanyang.ac.kr](mailto:koy8497@hanyang.ac.kr)

<sup>1</sup>Departments of Neurosurgery, College of Medicine, Hanyang University, 17 Haengdang-dong, Seongdong-gu, 133-792 Seoul, Republic of Korea  
Full list of author information is available at the end of the article





**Fig. 1** Preoperative imaging. Axial computed tomography (CT) scan with bone window (a) shows a destructive osteolytic mass lesion in the right temporal-posterior fossa region. Coronal CT scan (b) and magnetic resonance imaging (c) revealed an 8 × 7 cm homogenous mass extending to the cervical region

was easily peeled off. For the cervical part of the tumor, the major vessels were secured inferiorly, and the mass was removed up to the skull base. The tumor was removed entirely, except for a small portion around the jugular foramen to avoid lower cranial nerve injury. Finally, the large empty space was filled with a sternocleidomastoid muscle flap (Fig. 2). There were no neurological deficits after surgery.

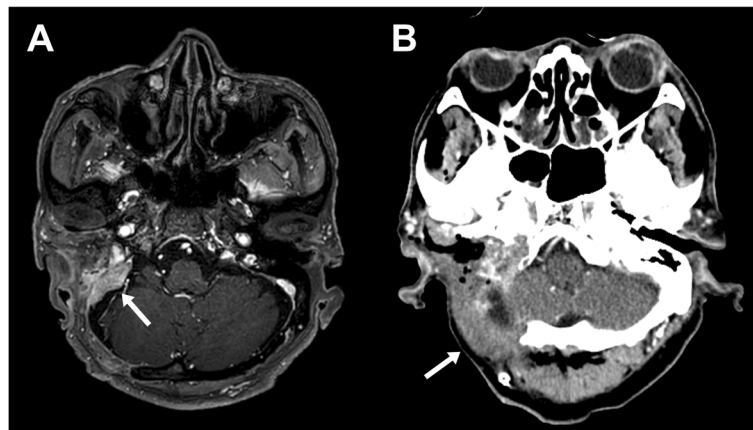
Histopathological studies confirmed a WHO (World Health Organization) grade II atypical meningioma with up to 6 mitoses per 10 high-power fields (Fig. 3). The Ki-67 proliferation index was 15%. The results of immunohistochemical staining are provided in Additional file 1: Figure S1.

### Discussion and conclusions

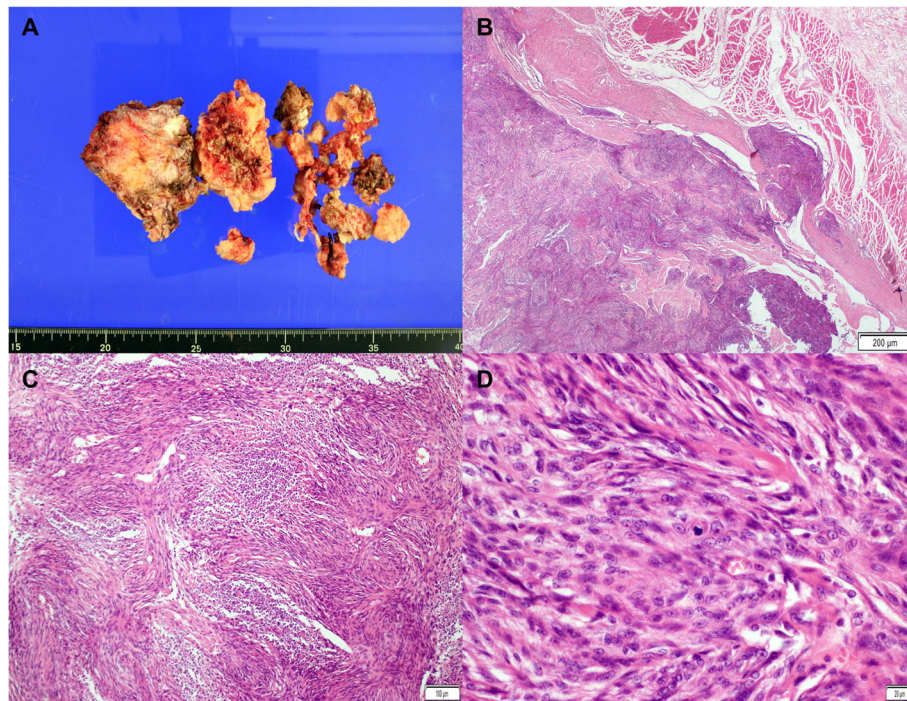
Primary intraosseous meningiomas are rare cranial lesions that arise from the bone, and they represent the

most common type of primary extradural meningiomas [1–3]. The majority of intraosseous meningiomas are osteoblastic and cause hyperostosis, which may mimic fibrous dysplasia. In contrast, and more rarely, they may present as an osteolytic skull lesion [6, 7]. Reportedly, less than 20% of intraosseous meningiomas are osteolytic [8].

Primary extradural meningiomas are most commonly found in skull convexities, the paranasal sinus, and the middle ear but rarely in the skull base. Liu et al. reported 170 cases of extradural meningiomas in the head, and only 5.8% were located in the skull base [9]. Notably, there are few reports of osteolytic intraosseous meningiomas in the skull base. To date, 50 cases of osteolytic subtypes (including the present case) have been reported in the English literature (Table 1). Of these, only seven were located in the skull base, and all but two originated from the petrous bone.



**Fig. 2** Postoperative magnetic resonance imaging (a) shows a small residual tumor around the jugular foramen, and computed tomography scan (b) demonstrates the sternocleidomastoid muscle which fills the tumor removal space



**Fig. 3** Histopathologic findings of atypical meningioma. The fragmented specimen (a) is seen as grayish-white solid masses. On microscopic examination, the tumor infiltrated the adjacent soft tissue (b, hematoxylin and eosin [H&E] stain,  $\times 20$ , scale bar = 200  $\mu\text{m}$ ) and showed a whorled appearance and multifocal necrosis (c, H&E stain,  $\times 100$ , scale bar = 100  $\mu\text{m}$ ). The tumor cells are composed of spindle cells with prominent nucleoli and ill-defined cytoplasm. Many mitoses are visible (d, H&E stain,  $\times 400$ , scale bar = 20  $\mu\text{m}$ )

The exact origin of extradural meningiomas is unclear, but several theories have been proposed. Their unusual locations are assumed to be the result of the aberrant differentiation or misplacement of undifferentiated mesenchymal stem cells [51]. Alternatively, extradural meningiomas may arise from differentiated arachnoid cap cells associated with blood vessels or nerves traversing the skull [52, 53]. Another theory proposes that they originate from arachnoid cap cells that get trapped in the cranial sutures during embryogenesis or molding of the cranium at birth [20, 21, 54]. Trauma with skull fracture has also been proposed as a causative factor of some extradural meningiomas, suggesting direct dural entrapment within bone fragments at the time of trauma [55].

The osteolytic subtype of intraosseous meningiomas is often misdiagnosed as a primary or secondary bone tumor due to its radiological appearance. The differential diagnosis of a solitary osteolytic skull lesion includes hemangioma, chondroma, chondrosarcoma, eosinophilic granuloma, epidermoid cyst, giant cell tumor, myeloma, and metastatic skull tumor [6, 23, 33].

Primary extradural meningiomas were practically classified according to their location by Lang and

colleagues (Table 2) [3]. Therefore, intraosseous meningiomas could be considered Type II or Type III extradural meningiomas. Based on this classification, the present case falls into the type IIIB category due to the presence of extracalvarial extension. This classification is helpful in predicting the risk of tumor recurrence. The IIC and IIIC subtypes rarely recur after complete resection, whereas the IIB and IIIB subtypes have a reported lifetime risk of recurrence of 26% [3].

Histopathological features are also important factors affecting tumor recurrence and prognosis. Recurrence was noted in 22% of benign intraosseous meningiomas in the literature, while it was reportedly 33% in cases of tumors with atypical or malignant pathology. In addition, aggressive atypical or malignant meningiomas had a significantly higher mortality of 29% compared to tumors with benign features (4.8%) [3]. Osteolytic meningiomas may have a higher incidence of atypical or malignant features [6]. In previous reports, benign features were reported in 87–89% of all extradural meningiomas, whereas in our literature review of osteolytic intraosseous meningiomas, 26% of cases were WHO grade II or III [3, 8].

**Table 1** Reports of primary intraosseous osteolytic meningiomas

Reference, year	Sex/age	Location	Type	Pathology
Klein et al., 1975 [10]	F/66	Parietal	IIIC	Meningothelial
McWhorter et al., 1976 [11]	M/42	Temporal	IIC	Benign
Palma et al., 1977 [12]	M/18	Frontal	IIIC	Fibroblastic
Pearl et al., 1979 [13]	F/44	Frontal	IIC	Meningothelial
Ohaegbulam et al., 1979 [14]	M/31	Frontal	IIIC	Fibroblastic
Young et al., 1983 [15]	M/71	Frontal	IIC	Benign
Kaneko et al., 1988 [16]	F/71	Frontoparietal	IIIC	Fibroblastic
Lee et al., 1988 [17]	F/71	Frontoparietal	IIC	Malignant
Oka et al., 1989 [18]	F/79	Frontoparietal	IIIC	Transitional
Ammirati et al., 1990 [19]	M/21	Petrous	IIIB	Benign
Kulali et al., 1991 [20]	M/50	Occipital	IIIC	Transitional
Ito et al., 1992 [21]	F/72	Frontoparietal	IIC	Meningothelial
Fujita et al., 1993 [22]	M/42	Petrous	IIIB	Malignant
Ghobashy and Tobler, 1994 [23]	F/65	Frontal	IIC	Transitional
Parington et al., 1995 [24]	F/84	Frontotemporal	IIIC	Atypical
Levin et al., 1995 [25]	N/A	Calvaria	N/A	N/A
Kuzeyli et al., 1996 [26]	M/6	Temporal	IIC	Meningothelial
Changhong et al., 1997 [27]	F/42	Occipital	IIC	Malignant
Muthukumar et al., 1997 [28]	M/55	Parietal	IIIC	Meningothelial
	M/50	Temporoparietal	IIC	Meningothelial
	M/60	Frontal	IIIC	Meningothelial
Kudo et al., 1998 [29]	F/56	Parietooccipital	IIIC	Meningothelial
Okamoto et al., 2000 [30]	F/78	Parietal	IIC	Microcystic
Yamazaki et al., 2001 [31]	M/62	Occipital	IIIB	Meningothelial
Rosahl et al., 2004 [32]	M/38	Petrous	IIB	Meningothelial
Tokgoz et al., 2005 [33]	M/44	Frontoparietal	IIIC	Chordoid
Bassiouni et al., 2006 [34]	M/47	Parietal	IIIC	Benign
	F/46	Temporal	IIC	Meningothelial
	F/57	Parietal	IIC	Fibroblastic
	F/62	Frontal	IIC	Atypical
	M/34	temporal	IIIC	Meningothelial
Al-Khawaja et al., 2007 [35]	M/50	Parietal	IIC	Meningothelial
Sheikhrezaie et al., 2009 [36]	M/62	Frontoparietal	IIIC	Benign
Yener et al., 2009 [37]	M/78	Parietal	IIC	Meningothelial
Hong et al., 2010 [38]	M/52	Parietal	N/A	Benign

**Table 1** Reports of primary intraosseous osteolytic meningiomas (Continued)

Reference, year	Sex/age	Location	Type	Pathology
	M/73	Occipital	N/A	Anaplastic
Kim et al., 2012 [39]	M/68	Parietal	IIIC	Atypical
	F/74	Frontal	IIIC	Papillary
Akhaddar and Ennoui, 2014 [40]	F/37	Frontal	IIC	Meningothelial
Tang et al., 2014 [41]	F/82	Parietal	IIC	Meningothelial
Yun and Lee, 2014 [42]	F/65	Frontal	IIIC	Atypical
Kim et al., 2014 [43]	F/44	Sphenoid	IIIB	Transitional
Bujok and Bienioszek, 2014 [44]	F/59	Frontal	IIC	Microcystic
Kwon et al., 2015 [45]	M/69	Parietal	IIIC	Meningothelial
Hong et al., 2015 [46]	M/61	Frontoparietal	IIC	Benign
Ben Nsir et al., 2016 [47]	M/42	Petrous	IIIB	Clear cell
Bohara et al., 2016 [48]	M/38	Parietal	IIIC	Atypical
Mouri et al., 2017 [49]	F/76	Frontal	IIIC	Transitional
Richardson et al., 2017 [50]	M/23	Frontal	IIC	Benign
Present case	M/80	Petrous	IIIB	Atypical

Wide surgical excision is the main treatment for extradural meningiomas, and it is potentially curative if complete resection is achieved [6, 7]. In the present case, a small portion of the tumor near the jugular foramen could not be removed due to the possibility of cranial nerve injury. In the case of skull base lesions that cannot be totally resected, decompression of vital neural structures is performed.

In conclusion, we performed surgical treatment for a rare case of primary osteolytic intraosseous meningioma in the skull base with extension to the cervical area. The histopathologic diagnosis was atypical meningioma. If possible, complete resection is the treatment of choice, and serial follow-up should be done to confirm recurrence or progression.

**Table 2** Primary extradural meningioma classification by Lang et al. 2000 [3]

Type	Description	Subtype
I	Purely extracalvarial with no bony attachment	
II	Purely calvarial	B (skull base) C (convexity)
III	Calvarial with extracalvarial extension	B (skull base) C (convexity)

## Additional file

**Additional file 1: Figure S1.** Immunohistochemical staining results. The tumor showed a wild-type p53 pattern (A,  $\times 200$ ) and exhibited strong cytoplasmic expression of  $\beta$ -catenin (B,  $\times 200$ ). Some tumor cells exhibited weak membranous expression of EGFR (C,  $\times 200$ ). The tumor was negative for Bcl-2 (D,  $\times 200$ ). The tumor shows membrane and cytoplasmic immunopositivity for EMA (E,  $\times 200$ ) and negative for S-100 protein (F,  $\times 200$ ). Vimentin is diffusely expressed in the cytoplasm of tumor cells (G,  $\times 200$ ). The Ki-67 proliferation index is estimated to be approximately 15% (H,  $\times 200$ ). Scale bar = 100  $\mu$ m. (DOCX 8214 kb)

### Abbreviations

CT: Computed tomography; MRI: Magnetic resonance imaging; WHO: World Health Organization

### Acknowledgements

Not applicable.

### Authors' contributions

SMK collected data and drafted the manuscript. YK critically revised the manuscript and supervised the study. SSB performed the pathological analysis. All authors revised the manuscript and approved the final version.

### Funding

Not applicable.

### Availability of data and materials

Not applicable.

### Ethics approval and consent to participate

This study was approved by the institutional review board of Hanyang University Medical Center.

### Consent for publication

Written informed consent was obtained from the patient for publication of this Case Report and any accompanying images. A copy of the signed consent form is available for review by the Editor of this journal.

### Competing interests

The authors declare that they have no competing interests.

### Author details

<sup>1</sup>Departments of Neurosurgery, College of Medicine, Hanyang University, 17 Haengdang-dong, Seongdong-gu, 133-792 Seoul, Republic of Korea. <sup>2</sup>Department of Neurosurgery, Keimyung University School of Medicine, 1095 Dalgubeol-daero, Dalseo-gu, Daegu 42601, Republic of Korea. <sup>3</sup>Departments of Pathology, College of Medicine, Hanyang University, 17 Haengdang-dong, Seongdong-gu, 133-792 Seoul, Republic of Korea.

Received: 26 February 2018 Accepted: 3 July 2019

Published online: 23 July 2019

### References

- Agrawal V, Ludwig N, Agrawal A, Bulsara KR. Intraosseous Intracranial Meningioma. *Am J Neuroradiol.* 2007;28:314–5.
- Muzumdar DP, Vengsarkar US, Bhatjwale MG, Goel A. Diffuse calvarial meningioma: a case report. *J Postgrad Med.* 2001;47:116.
- Lang FF, Macdonald OK, Fuller GN, DeMonte F. Primary extradural meningiomas: a report on nine cases and review of the literature from the era of computerized tomography scanning. *J Neurosurg.* 2000;93:940–50.
- Nicolay S, De Foer B, Bernaerts A, Van Dinther J, Parizel PM. A case of a temporal bone meningioma presenting as a serous otitis media. *Acta Radiol Short Rep.* 2014;3:2047981614555048.
- Hoye SJ, Hoar CS, Murray JE. Extradural meningioma presenting as a tumor of the neck. *Am J Surg.* 1960;100:486–9.
- Elder JB, Atkinson R, Zee C-S, Chen TC. Primary intraosseous meningioma. *Neurosurg Focus.* 2007;23:E13.
- Crawford TS, Kleinschmidt-DeMasters BK, Lillehei KO. Primary intraosseous meningioma. Case report. *J Neurosurg.* 1995;83:912–5.
- Mattox A, Hughes B, Oleson J, Reardon D, McLendon R, Adamson C. Treatment recommendations for primary extradural meningiomas. *Cancer.* 2011;117:24–38.
- Liu Y, Wang H, Shao H, Wang C. Primary extradural meningiomas in head: a report of 19 cases and review of literature. *Int J Clin Exp Pathol.* 2015;8:5624.
- Klein EW, Farhat SM, Hoskins PA, Colvin JT. Radionuclide cerebral angiographic evaluation of a diploic extracranial meningioma: case report. *J Nucl Med Off Publ Soc Nucl Med.* 1975;16:833–4.
- McWhorter JM, Ghatak NR, Kelly DL. Extradural meningioma presenting as lytic skull lesion. *Surg Neurol.* 1976;5:223–4.
- Palma L, Mercuri S, Ferrante L. Epidural calvarial meningioma. *Surg Neurol.* 1977;8:315–8.
- Pearl GS, Takei Y, Parent AD, Boehm WM. Primary intraosseous meningioma presenting as a solitary osteolytic skull lesion: case report. *Neurosurgery.* 1979;4:269–70.
- Ohaegbulam SC. Ectopic epidural calvarial meningioma. *Surg Neurol.* 1979;12:33–5.
- Young PH. Solitary subcutaneous meningioma appearing as an osteolytic skull defect. *South Med J.* 1983;76:1039–40.
- Kaneko F, Takase K, Nishiyama K, Kusaka K, Morizumi H, Matsumoto K. Report of a case of intraosseous meningioma. *No Shinkei Geka.* 1988;16:197–202.
- Lee WH, Tu YC, Liu MY. Primary intraosseous malignant meningioma of the skull: case report. *Neurosurgery.* 1988;23:505–8.
- Oka K, Hirakawa K, Yoshida S, Tomonaga M. Primary calvarial meningiomas. *Surg Neurol.* 1989;32:304–10.
- Ammirati M, Mirzai S, Samii M. Primary intraosseous meningiomas of the skull base. *Acta Neurochir (Wien).* 1990;107:56–60.
- Kulali A, Ilçayto R, Rahmanli O. Primary calvarial ectopic meningiomas. *Neurochirurgia (Stuttg).* 1991;34:174–7.
- Ito H, Takagi H, Kawano N, Yada K. Primary intraosseous meningioma: case report. *J Neurooncol.* 1992;13:57–61.
- Fujita T, Nakagawa H, Tsuruzono K, Izumoto S, Kadota T, Wada A. Extradural temporal meningioma directly extended to cervical bone—case report. *Neurol Med Chir (Tokyo).* 1993;33:458–62.
- Ghobashy A, Tobler W. Intraosseous calvarial meningioma of the skull presenting as a solitary osteolytic skull lesion: case report and review of the literature. *Acta Neurochir (Wien).* 1994;129:105–8.
- Partington MD, Scheithauer BW, Piepgras DG. Carcinoembryonic antigen production associated with an osteolytic meningioma. Case report. *J Neurosurg.* 1995;82:489–92.
- Levin M, Wertheim SE, Klein E, Lowry J. Unusual lytic intraosseous meningioma. *J Neuroimaging Off J Am Soc Neuroimaging.* 1995;5:247–8.
- Kuzeyli K, Duru S, Baykal S, Usul H, Ceylan S, Aktürk F. Primary intraosseous meningioma of the temporal bone in an infant. A case report. *Neurosurg Rev.* 1996;19:197–9.
- Changhong L, Naiyin C, Yuehuan G, Lianzhong Z. Primary intraosseous meningiomas of the skull. *Clin Radiol.* 1997;52:546–9.
- Muthukumar N. Primary calvarial meningiomas. *Br J Neurosurg.* 1997;11:388–92.
- Kudo H, Maeda S, Takamoto T, Tamaki N. Intraosseous meningioma with a dural defect. *Neurol Med Chir (Tokyo).* 1998;38:229–31.
- Okamoto S, Hisaoka M, Aoki T, Kadoya C, Kobanawa S, Hashimoto H. Intraosseous microcystic meningioma. *Skeletal Radiol.* 2000;29:354–7.
- Yamazaki T, Tsukada A, Uemura K, Satou H, Tsuboi K, Nose T. Intraosseous meningioma of the posterior fossa—Case report. *Neurol Med Chir (Tokyo).* 2001;41:149–53.
- Rosahl SK, Mirzayan M-J, Samii M. Osteolytic intra-osseous meningiomas: illustrated review. *Acta Neurochir (Wien).* 2004;146:1245–9.
- Tokgoz N, Oner YA, Kaymaz M, Ucar M, Yilmaz G, Tali TE. Primary intraosseous meningioma: CT and MRI appearance. *AJNR Am J Neuroradiol.* 2005;26:2053–6.
- Bassiouni H, Asgari S, Hübschen U, König H-J, Stolke D. Dural involvement in primary extradural meningiomas of the cranial vault. *J Neurosurg.* 2006;105:51–9.
- Al-Khawaja D, Murali R, Sindler P. Primary calvarial meningioma. *J Clin Neurosci Off J Neurosurg Soc Australas.* 2007;14:1235–9.
- Sheikhrezaie A, Meybodi AT, Hashemi M, Shafiee S. Primary intraosseous osteolytic meningioma of the skull: a case report. *Cases J.* 2009;2:7413.

37. Yener U, Bayrakli F, Vardereci E, Sav A, Peker S. Intradiploic meningioma mimicking calvarial metastasis: case report. *Turk Neurosurg.* 2009;19:297–301.
38. Hong B, Hermann EJ, Klein R, Krauss JK, Nakamura M. Surgical resection of osteolytic calvarial lesions: clinicopathological features. *Clin Neurol Neurosurg.* 2010;112:865–9.
39. Kim H, Jung T-Y, Kim I-Y, Lee J-K. Two cases of primary osteolytic intraosseous meningioma of the skull metastasizing to whole skull and the spine. *J Korean Neurosurg Soc.* 2012;51:151–4.
40. Akhaddar A, Ennouali H. Intraosseous extradural meningioma of the frontal bone. *Pan Afr Med J.* 2014;17:69.
41. Tang V, Lam M, Lai A. Intraosseous meningioma mimicking a metastasis. *BMJ Case Rep.* 2014;2014.
42. Yun J-H, Lee S-K. Primary osteolytic intraosseous atypical meningioma with soft tissue and dural invasion: report of a case and review of literatures. *J Korean Neurosurg Soc.* 2014;56:509–12.
43. Kim HS, Kim SH, Kim HJ, Kang SW, Kim SJ, Lee JH, et al. Primary Benign Intraosseous Meningioma on (18)F-FDG PET/CT Mimicking Malignancy. *Nucl Med Mol Imaging.* 2014;48:153–6.
44. Bujok J, Bienioszek M. Microcystic variant of an intraosseous meningioma in the frontal area: a case report. *Case Rep Neurol Med.* 2014;2014:527267.
45. Kwon SY, Shin HS, Kim TH, Kim HJ. Primary Intraosseous Osteolytic Meningioma of the Skull Mimicking Scalp Mass: A Case Report and Review of Literature. *Brain Tumor Res Treat.* 2015;3:151–5.
46. Hong SC, Woon K, O'Keefe B. Brain mushroom: A case of osteolytic intraosseous meningioma with transcalvaria herniation. *Br J Neurosurg.* 2015;29:876–8.
47. Ben Nsir A, Ben Hamouda K, Hammedi F, Kilani M, Hattab N. Osteolytic clear cell meningioma of the petrous bone occurring 36 years after posterior cranial fossa irradiation: Case report. *Neurol Neurochir Pol.* 2016;50:297–302.
48. Bohara S, Agarwal S, Khurana N, Pandey PN. Primary intraosseous atypical inflammatory meningioma presenting as a lytic skull lesion: Case report with review of literature. *Indian J Pathol Microbiol.* 2016;59:386–8.
49. Mouri G, Suzuki H, Hatazaki S, Matsubara T, Taki W. Skull Meningioma Associated with Intradural Cyst: A Case Report. *Clin Med Insights Case Rep.* 2017;10:1179547617738231.
50. Richardson TE, Georgescu M-M, Kapur P, Hwang H, Barnett SL, Raisanen JM, et al. Unusual skull tumors with psammomatoid bodies: a diagnostic challenge. *Clin Neuropathol.* 2017;36(2017):114–20.
51. Shuangshoti S, Netsky MG, Fitz-Hugh GS. Parapharyngeal meningioma with special reference to cell of origin. *Ann Otol Rhinol Laryngol.* 1971;80:464–73.
52. Perzin KH, Pushparaj N. Nonepithelial tumors of the nasal cavity, paranasal sinuses, and nasopharynx. A clinicopathologic study. XIII: Meningiomas. *Cancer.* 1984;54:1860–9.
53. Pompili A, Caroli F, Cattani F, Iachetti M. Intradiploic meningioma of the orbital roof. *Neurosurgery.* 1983;12:565–8.
54. Azar-Kia B, Sarwar M, Marc JA, Schechter MM. Intraosseous meningioma. *Neuroradiology.* 1974;6:246–53.
55. Turner OA, Laird AT. Meningioma with traumatic etiology. Report of a case. *J Neurosurg.* 1966;24:96–8.

## Publisher's Note

Springer Nature remains neutral with regard to jurisdictional claims in published maps and institutional affiliations.

**Ready to submit your research? Choose BMC and benefit from:**

- fast, convenient online submission
- thorough peer review by experienced researchers in your field
- rapid publication on acceptance
- support for research data, including large and complex data types
- gold Open Access which fosters wider collaboration and increased citations
- maximum visibility for your research: over 100M website views per year

**At BMC, research is always in progress.**

Learn more [biomedcentral.com/submissions](https://biomedcentral.com/submissions)

