

CASE REPORT

Open Access



Chronic inflammatory demyelinating polyneuropathy and psoriasis comorbidity with significantly alleviated in symptoms after secukinumab: case report

Yan Jin[†], Hong Chu[†], Hongjuan Dong, Hongyang Wang, Qingping Wang, Xiaoquan Zhao, Dongdong Qin, Zuneng Lu^{*}  and Chao Weng^{*}

Abstract

Background: Chronic inflammatory demyelinating polyneuropathy (CIDP) is an autoimmune disease that involves damage to the peripheral nervous system. The course of the disease can progress for more than 8 weeks, with frequent incidences of relapse-remission courses. This article reported a rare combination of CIDP with fluctuating symptoms, recurrence-remission, and comorbidity with psoriasis.

Case presentation: A 29-year-old male patient with repeated limb weakness and numbness was admitted to the hospital several times in the past six months. He had a history of psoriasis for 6 years, and the medications (clobetasol propionate ointment and calcipotriol ointment) treated for psoriasis were discontinued 1 year ago. During the hospitalization, repeated intravenous injections of human immunoglobulin G (IVIg), immunoadsorption, and secukinumab were performed. Nerve electrophysiology tests, ganglioside autoantibody spectrum tests, and clinical MRC muscle strength scores were performed on a regular basis to confirm the diagnosis of CIDP. The patient was regularly followed up.

Results: After repeated rounds of human IVIg and immunoadsorption, the patient's MRC score was increased by ≥ 6 points. The first ganglioside autoantibody spectrum test showed anti-GQ1b IgG (+) and anti-GM1 IgM (+) antibodies, and all were negative after re-examination. Finally, the patient was treated with the IL-17A inhibitor secukinumab for psoriasis. During 7 months of follow-up, the CIDP and psoriasis symptoms are relatively stable.

Conclusion: Combination of IVIg and immunoadsorption was highly effective in treating CIDP complicated with psoriasis. The clinical manifestations of CIDP are diverse. When relapse-remission occurs in the course of the disease, it is necessary to clarify whether it is combined with other autoimmune diseases and should control the autoimmune diseases as soon as possible.

Keywords: Chronic inflammatory demyelinating polyneuropathy, Psoriasis, Immunomodulatory therapy, Treatment, Case report

Background

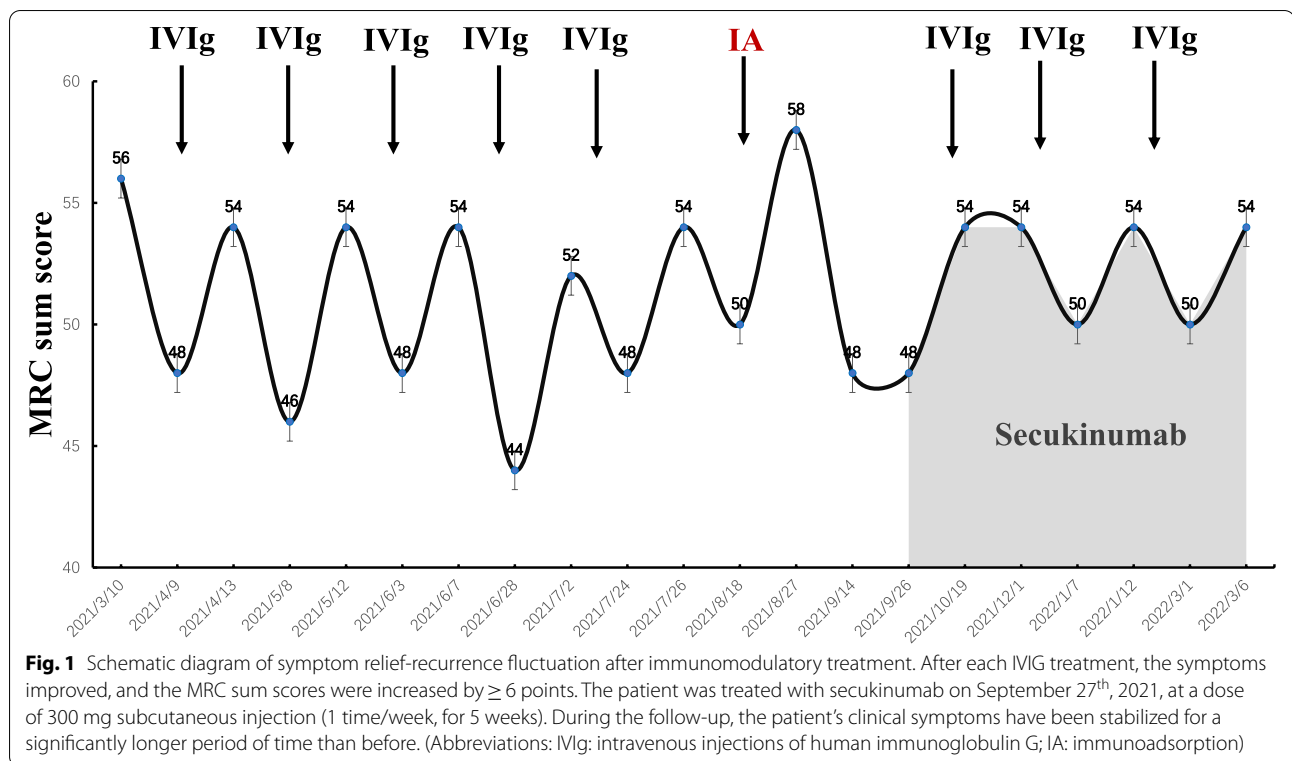
Chronic inflammatory demyelinating polyneuropathy (CIDP) is characterized by the progressive loss of myelin sheaths on the peripheral nerve fibers, leading to impaired motor and sensory functions in the

[†]Yan Jin and Hong Chu contributed equally to this work.

*Correspondence: lzn196480@126.com; wengch@whu.edu.cn

Department of Neurology, Renmin Hospital of Wuhan University, Hubei Province, Wuhan 430060, People's Republic of China





legs and arms and hyperactivation of neuroinflammatory responses as well [1]. As reports indicate, CIDP accounts for the overall prevalence rate of 0.67 ~ 10.3 cases per 100,000 persons, with an incidence rate of 0.15 ~ 10.6 cases per 100,000 individuals [2]. Although the pathomechanistic involvement of immune B and T cells has been implicated in the disease onset and progression, however, the exact underlying mechanisms remain unclear to date. Notably, CIDP exhibits diverse clinic-pathological symptoms, and the treatment outcomes vary greatly between the individual patients. Because of the significant contribution of the secondary complications, diagnostic precision and selection of the best possible therapeutic strategy have been challenging. Psoriasis is a common chronic skin disease associated with systemic inflammatory alterations in combination with the genetic and/or environmental etiology [3]. The prevalence of psoriasis is relatively less in the Chinese population (0.3%) [4] compared to the Europeans and North Americans (2%) [5]. Therefore, the concurrence of CIDP and psoriasis is a rare disease phenotype in any population. Here, we reported a rare case of CIDP combined with plaque psoriasis to further enrich our understanding of the diagnosis and treatment options and to reveal the underlying pathomechanisms.

Case presentation

A 29-year-old man was re-admitted to our hospital on September 9th, 2021, presenting with the symptoms of repeated limb weakness and numbness for half a year, and then suddenly aggravated for the past 3 days prior to the hospitalization. Six months ago, the patient reportedly had symptoms of muscle weaknesses in hands and legs, such as extreme difficulties in hand straightening, twisting bottle cap, standing up after squatting, and restricted walking ability as well, without any obvious cause. Later, he developed numbness in his limbs and muscle aches. During his initial visits to another hospital, he was initially diagnosed with the " Guillain-Barré syndrome ", which was later modified to be diagnosed with CIDP, and prescribed oral prednisone tablets (40 mg/day) and mycophenolate mofetil dispersible tablets (Seccopine) (0.75 g/morning and 0.5 g/night) in early April. However, these drugs could not significantly improve his symptoms, so he stopped the treatment in August. During this period, he underwent 5 courses of intravenous immunoglobulin (IVIg) therapy (0.4 g/kg/d, 5 days/course, 1 time/month) in another hospital. He subjectively assumed that each IVIg therapy could significantly ameliorate the muscle weakness symptoms; and the Medical Research Council (MRC) sum scores were (0–60) increased by ≥ 6 points (Fig. 1). However, there was a recurrence of symptoms with further worsening in about half a month after each

course. The patient was admitted to our department on August 4th, 2021 due to aggravated limb weakness. Then, he was subjected to 3 courses of immunoadsorption (IA) treatment, which happened to relieve the symptoms completely. The MRC sum scores were increased to 58 points. He was discharged from our hospital on August 27th, 2021 and received oral azathioprine (100 mg/day). During this period, patients received acupuncture and exercise therapy as rehabilitation training. Unfortunately, his limb weakness and numbness drastically increased on September 6th, 2021, which brought him to our hospital for further treatment. The patient's past medical history indicated suffering from psoriasis for 6 years and treatment with clobetasol propionate ointment and calcipotriol ointment on an intermittent basis. He stopped taking the medications 1 year ago, resulting in the recurrence of more severe symptoms. Following that, the patient underwent traditional Chinese medicine therapy, including the mung bean bath as per the physician's direction. Immediately after that, the patient experienced increased severity of muscle weakness and psoriasis plaques. Dermatological examinations revealed patchy hypopigmentation spots on the skin areas of his torso and limbs, slightly scaly texture on the upper limbs, and erythema on his external auditory canal and scalp. His limb muscle strength test showed grade 4 on the MRC Scale for muscle strength with normal limb muscle tone. Clinically, his left biceps reflex disappeared, other upper limb tendon reflexes were weakened, lower limb tendon reflexes disappeared. His superficial sensations were slightly decreased. The auxiliary tests, including cerebrospinal fluid (CSF) biochemistry and immunity, exhibited significant upregulation of total protein (1424 mg/L) and albumin (770 mg/L), in addition to IgG (169.0 mg/L) and IgA (38.5 mg/L). Diffusion-weighted magnetic resonance imaging (MRI) of the head with contrast enhancement could not detect any abnormalities. On May 8th, 2021 the patient was tested for the ganglioside autoantibody panel titers indicating positivity for both anti-GQ1b IgG and IgM anti-GM1 antibodies. Further examination of the ganglioside autoantibody spectrum on September 10th, 2021, showed negative results. His previous (April 7th, 2021) nerve electrophysiology test results indicated multiple peripheral nerve damage foci in the extremities, primarily due to demyelination of motor and sensory fibers. The F wave latency of the extremities was significantly prolonged with the involvement of nerve roots. Two consecutive re-examination results on August 5th and 16th consistently showed multiple peripheral nerve damages, including both proximal and distal nerve roots, demyelination combined with axonal damage, among which demyelination was the most severe. Multiple nerve motor conduction blocks could be observed (Table 1).

Therefore, this patient fulfilled the recent diagnostic criteria of the typical CIDP [1].

To summarize the findings from our case studies and compare them with the treatment outcomes from any previous report, we searched multiple databases, including China National Knowledge Infrastructure (CNKI), Wanfang, Weipu, PubMed, EMBASE, and Cochrane, using the keywords "CIDP", "psoriasis" and "CIDP complicated with psoriasis". We identified a few case studies on this topic. For example, in a case report of CIDP with psoriasis, the patient exhibited improvement of sensory disturbances after receiving IVIg treatment at 400 mg/kg/d dose for 5 days. Two weeks later, the patient's psoriasis on the elbows, knees, and hips was also improved significantly, and there was no recurrence-remission during the treatment. This case study suggests that IVIg treatment can not only improve the symptoms of CIDP but also significantly improve psoriasis symptoms and may be an effective treatment for refractory psoriasis [6]. Furthermore, 3 patients with psoriasis reportedly developed CIDP after receiving treatment for anti-tumor necrosis factor alpha (TNF- α). Among them, 2 patients developed CIDP after using adalimumab to treat psoriasis, and 1 patient developed CIDP after using infliximab. But all of them achieved clinical stability after IVIg treatment [7–9] (Table 2).

Following the worsening of the patient's recurring symptoms, he was re-admitted to our department, where we integrated the opinions of multidisciplinary experts, such as dermatologists, rheumatologists, and immunologists, to initiate the IL-17A inhibitor, secukinumab, therapy at a dose of 300 mg (1 time/week for 5 weeks; maintenance treatment once every 4 weeks) via subcutaneous injection to control psoriasis symptoms, in combination with IVIg (total dose of 2.0 g/kg, divided into 5 days) and azathioprine (100 mg/day) treatments as the maintenance therapy. Although there is no sufficient evidence to recommend any particular drug as immunosuppressant or immunomodulatory drug, we used azathioprine to reduce the dose and increase the interval of the first-line treatment to find the lowest effective maintenance dose. Later, the patient's symptoms rapidly improved. At the most recent follow-up examinations, the CIDP and psoriasis symptoms are stable.

Discussion

Presently, the European Society of Neurology/Peripheral Nerve Society (EFNS/PNS) 2021 CIDP guidelines recommend that electrophysiological diagnosis (i.e. nerve conduction examination) play a major role in the precise detection of CIDP, supplemented with neuroimaging, CSF components test, and nerve biopsy [1]. The most effective first-line therapies include corticosteroids,

Table 1 Nerve conduction test results

	2021/04/07		2021/08/05		2021/08/16	
	Left	Right	Left	Right	Left	Right
Motor conduction studies						
Median nerve						
DML (ms)	5.58 *	7.4 *	8.71 *	9.04 *	8.84 *	10.5 *
CMAP (mV)	9.7	4.66 *	3 *	6.5	5.3 *	7.3
CV (elbow-wrist, m/s)	20.9 *	22.9 *	17.5 *	17.2 *	15.2 *	16.7 *
F—wave latency (ms)	33.3	30.4	-	-	NR	48.6 *
F-wave persistence(%)	40 *	43.8 *	-	-	NR	40 *
Ulnar nerve						
DML (ms)	3.66 *	4.5 *	5.42 *	5.17 *	5.15 *	5.32 *
CMAP (mV)	5.5 *	3.49 *	4.2 *	5.8 *	4.5 *	5.4 *
CV (below elbow-wrist, m/s)	29.1 *	23.2 *	23.2 *	16.7 *	19.8 *	21.3 *
F—wave latency (ms)	28.2	70.4 *	-	-	NR	NR
F-wave persistence(%)	40 *	60 *	-	-	NR	NR
Tibial nerve						
DML (ms)	4.95	7.6 *	6.77 *	5.92 *	6.74 *	6.25 *
CMAP (mV)	19.8	18.08	0.4 *	4.9 *	4.6 *	5.4 *
F—wave latency (ms)	93.6 *	96.8 *	-	-	NR	NR
F-wave persistence(%)	100	68.8 *	-	-	NR	NR
Peroneal nerve						
DML (ms)	5.98 *	7.6 *	8.5 *	8.54 *	8.42 *	10.4 *
CMAP (mV)	5.8	6.48	3.3	3.2	3.9	4.4
CV (fibular neck-ankle, m/s)	34.1 *	30.6 *	23.5 *	24.2 *	25.8 *	26.7 *
F—wave latency (ms)	89.5 *	-	-	-	NR	NR
F-wave persistence(%)	45.5 *	-	-	-	NR	NR
Sensory conduction studies						
Median nerve						
Peak latency (ms)	3.53	4.2	4.98	4.34	5.61	5.96
The SNAP (μ V)	10.3 *	7.73 *	5.5 *	7.5 *	8.3 *	4.4 *
CV (wrist-index finger, m/s)	34.8	32.7 *	28.1 *	32.3 *	25 *	23.5 *
Ulnar nerve						
Peak latency (ms)	3.74	3.9	4.09	3.86	4.77	4.77
The SNAP (μ V)	12.7 *	11.52 *	11.1 *	8.2 *	10.6 *	12.5 *
CV (wrist-little finger, m/s)	29.9 *	29.7 *	28.1 *	28.5 *	24.1 *	23.1 *
Radial nerve						
Peak latency (ms)	5.15	-	3.9	3.64	3.76	3.86
The SNAP (μ V)	5.2 *	-	8.4 *	9.6 *	4.5 *	7.2 *
CV (forearm-snuff box, m/s)	36.5 *	-	30.8 *	31.6 *	34.6 *	29.8 *
Sural nerve						
Peak latency (ms)	2.63	2.9	2.22	2.02	2.16	2.15
The SNAP (μ V)	17.5	11.51	11.8	14.7	19.1	27.8
CV (calf-ankle, m/s)	45.6	44.2	47.3	52	50.9	53.5
Superficial peroneal nerve						
Peak latency (ms)	-	3.2	2.41	2.6	2.47	2.69
The SNAP (μ V)	-	21.35	20.5	13.9	20.9	19
CV (lower leg-ankle, m/s)	-	40.6	45.6	44.2	44.5	42.8

NR no response, Absence of test, *Abnormal values

Abbreviations: DML distal motor latency, CMAP Compound motor action potential, CV conduction velocity, CMAP Compound motor action potential, SNAP Sensory nerve action potential

Table 2 Summary of literature on chronic inflammatory demyelinating polyneuropathy (CIDP) in psoriasis patients

Case	Gender	Age (years)	Previous biological treatment	Treatment	The curative effect
1 [6]	male	58	-	One IVIG treatment (400 mg/kg/d for 5 days)	Sensory impairment was significantly improved
2 [7]	male	49	Infliximab (5 mg/kg at weeks 0, 2, and 6, followed by an 8-week interval) was treated for 8 months	Monthly IVIG treatment (400 mg/kg/d, for 5 days)	Limb weakness was significantly improved, and clinical stability was achieved
3 [8]	male	42	Adamuzumab (80 mg twice weekly) was treated for 1 year	IVIG treatment (details not available)	CIDP recovered completely and no recurrence occurred during 5 months of follow-up
4 [9]	female	53	Adamuzumab (40 mg biweekly) was treated for 10 months	Four IVIG treatments (400 mg/kg/d for 5 days); Oral prednisolone (1 mg/kg, reduced at a rate of 10 mg every 2 weeks)	CIDP recovered completely and no recurrence occurred during 12 months of follow-up

IVIg, and plasma exchange (PE). Corticosteroids have inhibitory effects on a multitude of immune-modulatory functions, such as anti-inflammation, anti-immune, anti-allergic, and anti-shock abilities [10]. Moreover, IVIg can also interfere with the complement activity, production of pro-inflammatory cytokines, and the signal transduction of phagocytes and B cells through Fcγ receptors [11]. Both IA and PE can eliminate pathogenic factors, such as autoantibodies, activated complement, and inflammatory factors, from the blood of patients to achieve rapid and sustained treatment outcomes [12, 13]. In the case of our patient, we found a complete reversal of the first ganglioside autoantibody spectrum results in the subsequent re-examinations when the patient was subjected to the multiple rounds of IVIg and IA treatments, further suggesting that combination of these two approaches may establish potential treatment regimen for CIDP patients complicated with psoriasis.

The patient received IVIg treatment several times. After each IVIg treatment, the symptoms improved, and the MRC sum scores were (0–60) increased by ≥ 6 points. In August 2021, the patient's symptoms recurred with severity to the extent that he was immediately hospitalized. After several IA treatments, the patient's clinical symptoms were significantly relieved, and he was able to walk independently, although a little assistance was required in daily life. Notably, less than half a month later, the patient was re-admitted to the hospital because of severe worsening of the recurring symptoms (Fig. 1). The patient had a history of psoriasis for 6 years in the past. The medications (clobetasol propionate ointment and calcipotriol ointment) were discontinued one year ago, and his psoriasis condition was returned, further worsening the situation. It could be speculated that the CIDP pathogenesis might be related to psoriasis via a common potential immunopathogenic mechanism, which again might be related to the activation of Th17 cells to produce

IL-17 and other inflammatory factors (Flowchart 1). Currently, the patient's symptoms have not fluctuated and recurred during the follow-up, and the patient's clinical symptoms have been stabilized for a significantly longer period of time than before (Fig. 1). However, the efficacy of secukinumab still needs to be tested in the long-term follow-up observation. Individuals who are susceptible to autoimmune diseases may develop different kinds of autoimmune diseases, according to the co-stimulatory environment. However, the possibility of accidental onset of the two conditions cannot be ruled out, and further clinical and basic research is needed to confirm it.

Conclusion

In conclusion, the pathogenesis of CIDP is still unclear and the clinical symptoms are diverse. There are certain difficulties in the selection of treatment options, and the efficacy of CIDP treatment varies greatly between individuals. When CIDP patients do not respond well to the first-line treatment or the course of the disease follows the relapse-remission pattern, it is necessary to consider the possibilities of misdiagnosis, other immune diseases and/or insufficient immunotherapy doses [14]. CIDP combined with psoriasis is clinically a very rare disease phenotype. This patient further reminds clinicians that the clinical manifestations of CIDP are diverse. Therefore, early treatment outcomes in CIDP patients are very crucial, and the close monitoring of the relapse-remission instances along the treatment line can alert the clinicians to the possibility of underlying autoimmune complications, which need to be immediately and efficiently resolved for the long-term stabilization of clinical symptoms in such patients.

Abbreviations

CIDP: Chronic inflammatory demyelinating polyneuropathy; IVIg: Intravenous injections; MRC: The Medical Research Council; IL: Interleukin; IA: Immunoadsorption; CSF: Cerebrospinal fluid; MRI: Magnetic resonance imaging; TNF- α :

Tumor necrosis factor alpha; EFNS/PNS: The European Society of Neurology/Peripheral Nerve Society; PE: Plasma exchange.

Supplementary Information

The online version contains supplementary material available at <https://doi.org/10.1186/s12883-022-02928-3>.

Additional file 1: Flowchart 1. Diagram of the hypothesis of pathogenesis. Unknown antigens or environmental factors can trigger the activation of innate immune cells. These activated immune cells can produce a large number of inflammatory factors, such as interleukin (IL)-23 and TNF- α , which can induce the differentiation of primitive T cells into Th17 cells, and the activated Th17 cells then can overproduce IL-17 and IL-22, etc., promoting the proliferation of keratinocytes and recruiting pro-inflammatory cells, such as neutrophils, leading to the development of psoriasis [15]. At the same time, activated Th17 cells and their secreted cytokines IL-17 and IL-22 can destroy the blood-nerve barrier [16], followed by the activation of local intraneural immune responses, macrophage recruitment, and toxic factor secretion leading to myelin sheath injury and the development of CIDP [17]. IL-17 inhibits Schwann cell-mediated myelin regeneration [18]. The combination of factors complicates axonal injury and CIDP, and patients show relapse-remission patterns. Secukinumab can selectively target and bind to IL-17A to inhibit the interaction between IL-17A and IL-17 receptors [19, 20]. Finally, secukinumab can treat psoriasis while achieving clinical stability of CIDP symptoms.

Acknowledgements

We would like to thank dermatologist Professor Tiechi Lei for his guidance on psoriasis treatment. We thank Professor Zhiyong Liu, Department of Rheumatology, for his participation in the diagnosis and treatment of the disease.

Authors' contributions

YJ and HC: conception, organization and execution of the research project, writing of the first draft and the review and critique of the manuscript. HJD, HYW, QPW, XQZ, DDQ, ZNL and CW: conception, organization and execution of the research project, review and critique of the manuscript. All authors have read and approved the final manuscript.

Funding

No funding was received.

Availability of data and materials

All datasets generated for this study are included in the article.

Declarations

Ethics approval and consent to participate

Informed consent was obtained from the patient to publish this case, and approval for this study was provided by the Research Ethics Committee of Renmin Hospital of Wuhan University.

Consent for publication

Written informed consent was obtained from the patient for the publication of this case report, including any potentially identifiable images or data included in this article.

Competing interests

The authors report no conflicts of interest.

Received: 5 May 2022 Accepted: 21 October 2022

Published online: 02 November 2022

References

1. Van den Bergh PYK, van Doorn PA, Hadden RDM, Avau B, Vankrunkelven P, Allen JA, et al. European Academy of Neurology/Peripheral Nerve Society guideline on diagnosis and treatment of chronic inflammatory

- demyelinating polyradiculoneuropathy: Report of a joint Task Force-Second revision. *J Peripher Nerv Syst.* 2021;26(3):242–68. <https://doi.org/10.1111/jns.12455>.
2. Bunschoten C, Jacobs BC, Van den Bergh PYK, Cornblath DR, van Doorn PA. Progress in diagnosis and treatment of chronic inflammatory demyelinating polyradiculoneuropathy. *The Lancet Neurology.* 2019;18(8):784–94. [https://doi.org/10.1016/s1474-4422\(19\)30144-9](https://doi.org/10.1016/s1474-4422(19)30144-9).
3. Rendon A, Schakel K. Psoriasis Pathogenesis and Treatment. *Int J Mol Sci.* 2019;20(6); doi: <https://doi.org/10.3390/ijms20061475>.
4. Griffiths CEM, Barker JNWN. Pathogenesis and clinical features of psoriasis. *The Lancet.* 2007;370(9583):263–71. [https://doi.org/10.1016/s0140-6736\(07\)61128-3](https://doi.org/10.1016/s0140-6736(07)61128-3).
5. Boehncke W-H, Schön MP. Psoriasis. *The Lancet.* 2015;386(9997):983–94. [https://doi.org/10.1016/s0140-6736\(14\)61909-7](https://doi.org/10.1016/s0140-6736(14)61909-7).
6. Taguchi Y, Takashima S, Yoshida S, Dougu N, Inoue H, Tanaka K. Psoriasis improved by intravenous immunoglobulin therapy. *Intern Med.* 2006;45(14):879–80. <https://doi.org/10.2169/internalmedicine.45.1704>.
7. Foulkes AC, Wheeler L, Gosal D, Griffiths CE, Warren RB. Development of chronic inflammatory demyelinating polyneuropathy in a patient receiving infliximab for psoriasis. *Br J Dermatol.* 2014;170(1):206–9. <https://doi.org/10.1111/bjd.12572>.
8. Nakao M, Asano Y, Nakamura K, Shida R, Takahashi T, Yoshizaki A, et al. The development of chronic inflammatory demyelinating polyneuropathy during adalimumab treatment in a patient with psoriasis vulgaris. *Eur J Dermatol.* 2016;26(4):404–5. <https://doi.org/10.1684/ejd.2016.2781>.
9. Ahmed Z, Powell R, Llewelyn G, Anstey A. Chronic inflammatory demyelinating polyradiculoneuropathy complicating anti TNF alpha therapy for chronic plaque psoriasis. *BMJ Case Rep.* 2011;2011; doi: <https://doi.org/10.1136/bcr.08.2011.4674>.
10. Vandewalle J, Luybaert A, De Bosscher K, Libert C. Therapeutic Mechanisms of Glucocorticoids. *Trends Endocrinol Metab.* 2018;29(1):42–54. <https://doi.org/10.1016/j.tem.2017.10.010>.
11. Lehmann HC, Burke D, Kuwabara S. Chronic inflammatory demyelinating polyneuropathy: update on diagnosis, immunopathogenesis and treatment. *J Neurol Neurosurg Psychiatry.* 2019;90(9):981–7. <https://doi.org/10.1136/jnnp-2019-320314>.
12. Rodriguez Y, Vatti N, Ramirez-Santana C, Chang C, Mancera-Paez O, Gershwin ME, et al. Chronic inflammatory demyelinating polyneuropathy as an autoimmune disease. *J Autoimmun.* 2019;102:8–37. <https://doi.org/10.1016/j.jaut.2019.04.021>.
13. Dorst J, Fillies F, Dreyhaupt J, Senel M, Tumani H. Safety and Tolerability of Plasma Exchange and Immunoabsorption in Neuroinflammatory Diseases. *J Clin Med.* 2020;9(9); doi: <https://doi.org/10.3390/jcm9092874>.
14. Kieseier BC, Mathey EK, Sommer C, Hartung HP. Immune-mediated neuropathies. *Nat Rev Dis Primers.* 2018;4(1):31. <https://doi.org/10.1038/s41572-018-0027-2>.
15. Korman NJ. Management of psoriasis as a systemic disease: what is the evidence? *Br J Dermatol.* 2020;182(4):840–8. <https://doi.org/10.1111/bjd.18245>.
16. Chi LJ, Xu WH, Zhang ZW, Huang HT, Zhang LM, Zhou J. Distribution of Th17 cells and Th1 cells in peripheral blood and cerebrospinal fluid in chronic inflammatory demyelinating polyradiculoneuropathy. *J Peripher Nerv Syst.* 2010;15(4):345–56. <https://doi.org/10.1111/j.1529-8027.2010.00294.x>.
17. Wolbert J, Cheng MI, Meyer zu Horste G, Su MA. Deciphering immune mechanisms in chronic inflammatory demyelinating polyneuropathies. *JCI Insight.* 2020;5(3); doi: <https://doi.org/10.1172/jci.insight.132411>.
18. Stettner M, Lohmann B, Wolfram K, Weinberger JP, Dehmel T, Hartung HP, et al. Interleukin-17 impedes Schwann cell-mediated myelination. *J Neuroinflammation.* 2014;11:63. <https://doi.org/10.1186/1742-2094-11-63>.
19. Baraliakos X, Gossec L, Pournara E, Jeka S, Mera-Varela A, D'Angelo S, et al. Secukinumab in patients with psoriatic arthritis and axial manifestations: results from the double-blind, randomised, phase 3 MAXIMISE trial. *Ann Rheum Dis.* 2021;80(5):582–90. <https://doi.org/10.1136/annrheumdis-2020-218808>.
20. McInnes IB, Behrens F, Mease PJ, Kavanaugh A, Ritchlin C, Nash P, et al. Secukinumab versus adalimumab for treatment of active psoriatic arthritis (EXCEED): a double-blind, parallel-group, randomised, active-controlled, phase 3b trial. *The Lancet.* 2020;395(10235):1496–505. [https://doi.org/10.1016/s0140-6736\(20\)30564-x](https://doi.org/10.1016/s0140-6736(20)30564-x).

Publisher's Note

Springer Nature remains neutral with regard to jurisdictional claims in published maps and institutional affiliations.

Ready to submit your research? Choose BMC and benefit from:

- fast, convenient online submission
- thorough peer review by experienced researchers in your field
- rapid publication on acceptance
- support for research data, including large and complex data types
- gold Open Access which fosters wider collaboration and increased citations
- maximum visibility for your research: over 100M website views per year

At BMC, research is always in progress.

Learn more biomedcentral.com/submissions

